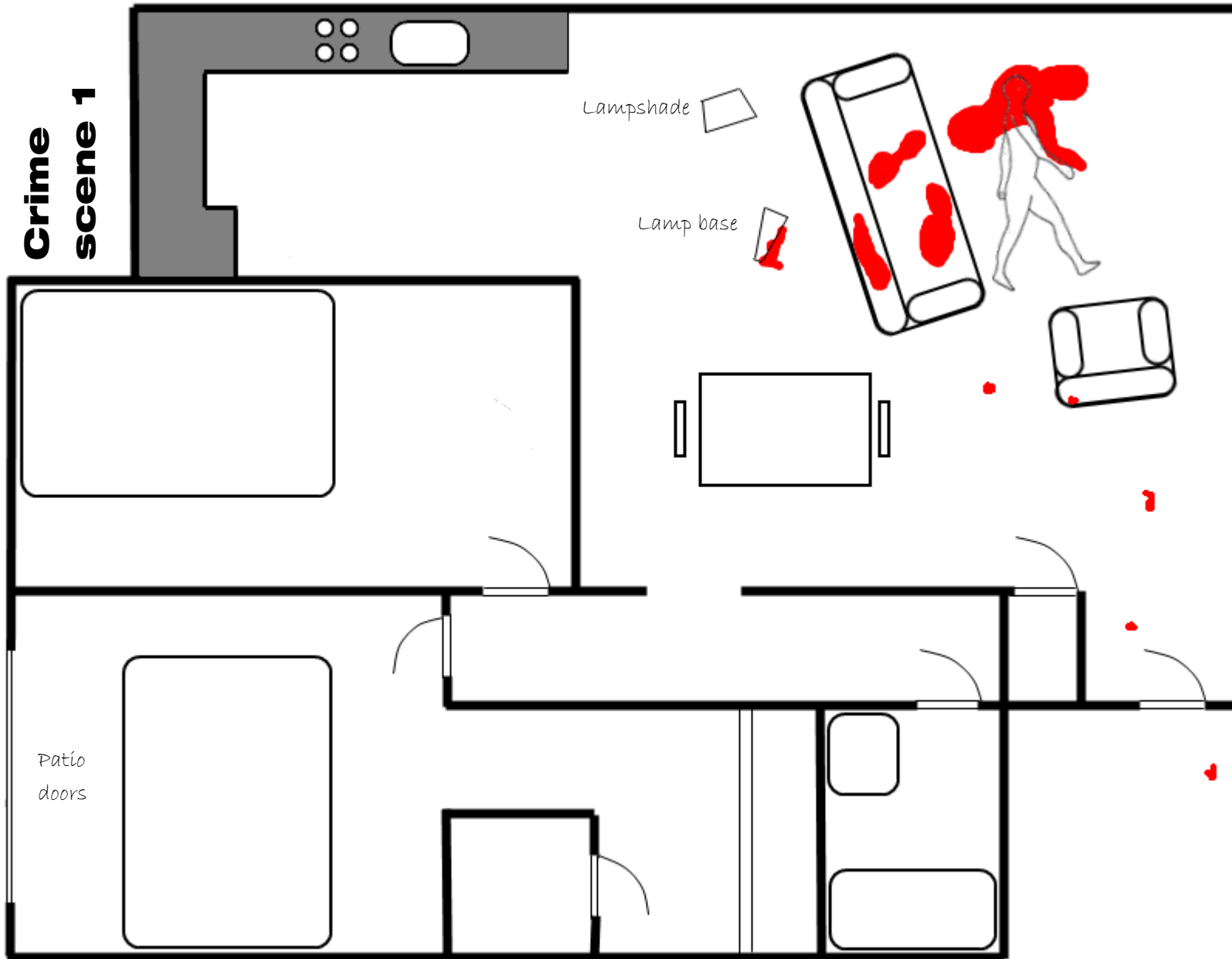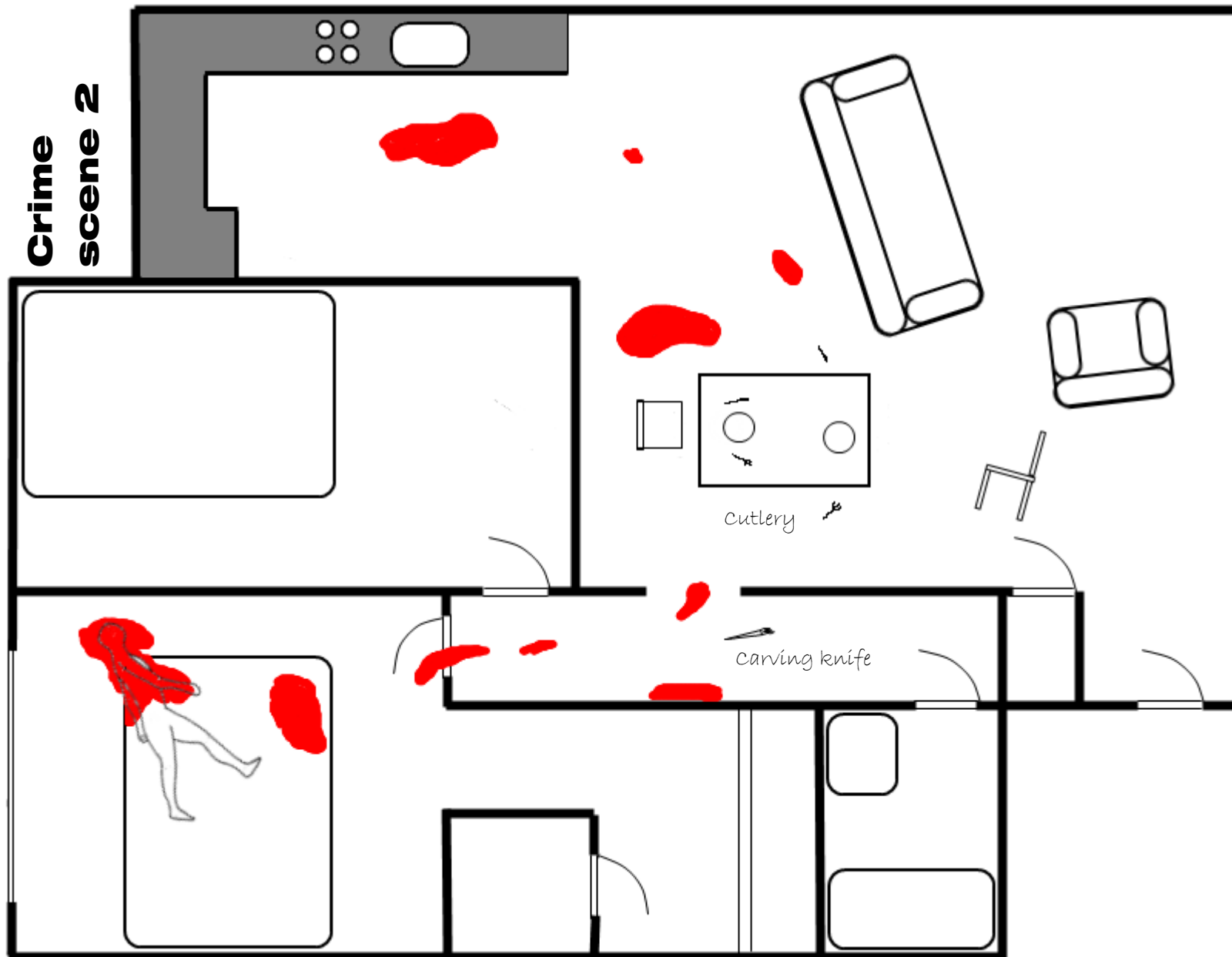


The victim was a Caucasian female aged 28 years.

She was found partially clothed on the floor of the living area. The cause of death was blunt force trauma to the head. There was one large, deep impact area on the rear of the skull and multiple impacts to the forehead, face and shoulders.

There were large patches of blood on the sofa and on the floor beneath the victim and extensive blood spatter on the walls and ceiling in the vicinity of the victim. There were smaller patches and smears of blood between the sofa and the front door, on the armchair and outside the front door. A lampshade and base were found on the floor of the living area

The contents of the flat did not appear to have been disturbed. The patio doors at the rear were open and the lock showed signs of having been forced. The front door was pushed to but not fully shut or locked.

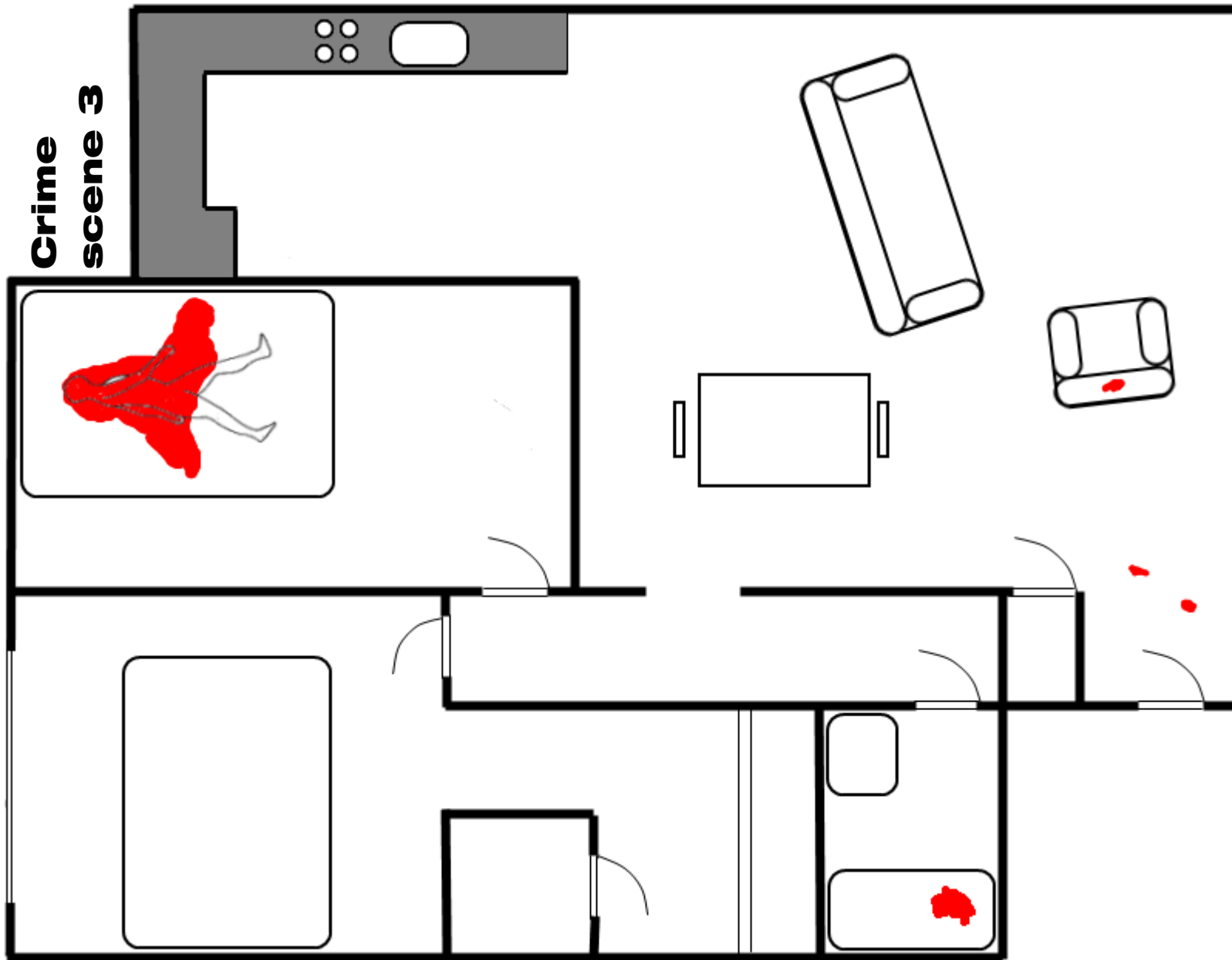


The victim was an Afro-Caribbean woman aged 25 years.

She was found fully clothed lying half on half off the bed in the larger of the two bedrooms. The cause of death was exsanguination. There were multiple stab wounds on the victim's neck, chest, forearms, hands and back. Those in the chest and neck were the deepest and most obviously fatal.

There were large patches of blood in the living area, the kitchen and the bedroom. In the bedroom there were two large bloodstains on the bed and another on the floor beneath the victim. There were smaller patches and smears of blood in the corridor and the bedroom doorway and traces in the bathroom sink.

Most areas of the flat appeared undisturbed although the living area was in some disarray. Cutlery was found on the floor and two half eaten plates of food on the table. All doors and windows were locked.



The victim was a Caucasian woman aged 45 years.

She was found naked on the bed in the smaller bedroom. Her wrists and ankles had been bound with industrial duct tape. The cause of death was exsanguination. There were forty five stab wounds on the victim's chest, abdomen and thighs. None of these were deep enough to be immediately fatal. Her throat had been deeply cut but it is not clear whether this occurred after her death.

There was a large patch of blood beneath the victim, enough to have soaked right through the bedding and mattress. Small traces of blood were found near the front door, on the armchair in the living area. Dilute blood was found in the shower/bath.

The contents of the flat appeared undisturbed, although some bedroom drawers were open. A pendant the victim was known to be wearing was not found.